

Polymyxin B Induced Facial Rash and Superficial Thrombophlebitis: A Dual Adverse Drug Reaction

Idris Dawaiwala^{1,*}, Soniya Bhagat¹, Kapil Zirpe², Aniket Shah³, Abhijeet Deshmukh⁴, Prasad Muglikar⁵

¹Department of Quality Assurance and Clinical Pharmacy, Ruby Hall Clinic, Grant Medical Foundation, Pune, Maharashtra, INDIA.

²Director, Department of Neurotrauma Unit, Ruby Hall Clinic, Grant Medical Foundation, Pune, Maharashtra, INDIA.

³Department of Surgical Oncology, Ruby Hall Clinic, Grant Medical Foundation, Pune, Maharashtra, INDIA.

⁴Department of Neurotrauma Unit, Ruby Hall Clinic, Grant Medical Foundation, Pune, Maharashtra, INDIA.

⁵Department of Medical Administration, Ruby Hall Clinic, Grant Medical Foundation, Pune, Maharashtra, INDIA.

ABSTRACT

Polymyxin B is a last-line therapy for multidrug-resistant Gram-negative infections, with nephrotoxicity and neurotoxicity being the most recognized adverse effects. Cutaneous and vascular complications are rare and underreported. We describe a 34-year-old male with carcinoma of the buccal mucosa who developed surgical site infection due to MDR *Klebsiella pneumoniae*. He received intravenous polymyxin B (0.75 million units per dose, twice daily, as per institutional ICU protocol), and on Day 4 developed a non-pruritic facial maculopapular rash and infusion-site pain with Doppler-confirmed superficial thrombophlebitis. Both resolved after drug withdrawal and supportive management. Causality assessment using Naranjo and WHO-UMC scales indicated a probable association. To our knowledge, this is the first Indian report of simultaneous dermatologic and vascular adverse reactions to polymyxin B. Early recognition and preference for central venous access may prevent complications and improve safety.

Keywords: Adverse drug reaction, Drug-induced rash, MDR *Klebsiella*, Polymyxin B, Thrombophlebitis.

Correspondence:

Dr. Idris Dawaiwala, PharmD

Department of Quality Assurance and Clinical Pharmacy, Ruby Hall Clinic, Pune, Maharashtra, INDIA.

Email: idrisd52@gmail.com

ORCID: 0000-0002-1769-2758

Received: 24-09-2025;

Revised: 14-11-2025;

Accepted: 02-01-2026.

INTRODUCTION

Polymyxin B has re-emerged as an essential antimicrobial agent against Multidrug-Resistant (MDR) Gram-negative pathogens such as *Klebsiella pneumoniae*, *Acinetobacter baumannii*, and *Pseudomonas aeruginosa* (Tsuji *et al.*, 2019; Lahiry *et al.*, 2017). Although nephrotoxicity and neurotoxicity are the most recognized adverse effects, cutaneous manifestations and infusion-related reactions such as thrombophlebitis are less frequently reported.

Emerging literature has identified delayed-onset facial hyperpigmentation and rash as possible adverse events with polymyxin B (Kura and Sonawane, 2023; Mattos *et al.*, 2017; Zheng *et al.*, 2018). Proposed mechanisms include non-IgE-mediated histamine release, inflammatory cytokine activation (e.g., IL-6), and melanocyte stimulation via MAPK and PKA pathways (Mattos *et al.*, 2017; Zheng *et al.*, 2018). In addition, the acidic nature and irritant profile of polymyxin B can cause

local vascular injury when administered peripherally (Vardakas and Falagas, 2017). Despite its life-saving potential, polymyxin B poses a dilemma between therapeutic benefit and Adverse Drug Reaction (ADR) risk. Given the increasing reliance on polymyxins in Indian ICUs, it is critical to document and analyze even uncommon adverse events. This not only contributes to pharmacovigilance data but also may influence future dosing protocols, infusion practices, and monitoring strategies.

We report a case of polymyxin B-induced facial rash and superficial thrombophlebitis in a young adult with MDR *Klebsiella* infection. This dual presentation has not been frequently reported in Indian patients and highlights preventable aspects of polymyxin B toxicity.

CASE REPORT

A 34-year-old male with carcinoma of the right buccal mucosa underwent wide local excision, marginal mandibulectomy, right neck dissection, and free flap reconstruction on 19 May 2025. He was readmitted to the Neuro Trauma Unit, Ruby Hall Clinic, Pune, India, on 12 June 2025 with signs of surgical site infection, including localized erythema, swelling, and purulent discharge from the operative site.

Initial differential diagnoses included deep space neck abscess and flap necrosis. Surgical site exploration ruled out necrosis



DOI: 10.5530/ijopp.20260624

Copyright Information :

Copyright Author (s) 2026 Distributed under Creative Commons CC-BY 4.0

Publishing Partner : Manuscript Technomedia. [www.mstechnomedia.com]

or abscess, and pus swab culture revealed MDR *Klebsiella pneumoniae* resistant to all tested β -lactams, carbapenems, aminoglycosides, and fluoroquinolones. The isolate was sensitive only to colistin (MIC 0.5 $\mu\text{g/mL}$). Polymyxin B was selected over colistin because it is administered as the active moiety (no prodrug conversion), enabling more predictable exposure and faster attainment of therapeutic concentrations in critically ill patients. In addition, its PK profile is less dependent on renal function, reducing variability in target attainment for severe MDR Gram-negative infections.

After a negative test dose, intravenous polymyxin B was initiated on 14 June 2025 at 1.25 mg/kg (Polymyxin B base activity, PBA) every 12 hr for a 60-kg patient (≈ 75 mg PBA per dose, equivalent to $\approx 750,000$ units or 0.75 million units per dose). The dosing regimen followed institutional ICU protocol and aligns with international consensus guidelines for optimal polymyxin B use (Tsuji *et al.*, 2019). Infusions were administered slowly over 2-3 hr with scheduled IV site rotation every 48 hr. On Day 4 (17 June), after the 7th dose of polymyxin B, the patient developed a non-pruritic maculopapular rash over the cheeks and perioral area without mucosal involvement or systemic symptoms, as shown in Figure 1. There was no associated fever or eosinophilia. Dermatology evaluation suggested a delayed hypersensitivity reaction. Although no biopsy was performed, differential diagnoses including viral exanthema, contact dermatitis, and drug-induced exanthem were considered less likely due to the lack of systemic symptoms, absence of new topical exposures, and the temporal association with polymyxin B initiation. The drug was discontinued on 17 June, and the rash resolved without corticosteroids.

On the same day, the patient complained of pain and swelling in the left upper limb at the previous IV site. Examination revealed localized induration, tenderness, and post-inflammatory hyperpigmentation. Venous Doppler revealed thrombosis in the cephalic, basilic, and median cubital veins with preserved deep venous flow, consistent with superficial thrombophlebitis.

Renal function and inflammatory markers were within normal limits except for a mildly elevated D-dimer (410 ng/mL). Thrombophilia screening, including lupus anticoagulant and antiphospholipid antibodies, was negative. Carotid Doppler and IJV imaging revealed no central vein thrombosis. Echocardiography showed normal cardiac structure and function (EF 60%) with no thrombus.

Medications administered from 14 to 17 June included polymyxin B, tigecycline, pantoprazole, and supportive IV fluids. Although tigecycline has been associated with cutaneous reactions in rare instances, it was continued throughout the course of therapy without exacerbation of the rash. Notably, the facial rash began improving even while tigecycline was ongoing, which further supports polymyxin B as the more likely culprit. Cetirizine was

initiated after rash onset. No NSAIDs, contrast agents, or known thrombogenic drugs were used during this period. The patient was managed with enoxaparin, Daflon, Chymoral Forte, and magnesium sulfate dressings. A central femoral line was inserted for subsequent IV therapy. Causality assessment using the Naranjo scale yielded a score of 7 (probable). WHO-UMC criteria similarly supported a probable/likely association. Rechallenge was considered unethical. A concise summary of the dual adverse reactions is provided in Table 1.

DISCUSSION

Polymyxin B remains a cornerstone for treating multidrug-resistant Gram-negative infections but is associated with notable toxicity risks. While nephrotoxicity and neurotoxicity are well recognized, cutaneous hypersensitivity reactions and local infusion-site complications are underreported (Tsuji *et al.*, 2019; Lahiry *et al.*, 2017).

Our patient developed a non-pruritic, non-vesicular facial maculopapular rash on Day 4 of treatment, which resolved promptly after discontinuation of polymyxin B. The localized rash, without systemic manifestations, aligns with previously reported delayed-onset cutaneous reactions to polymyxin B, potentially

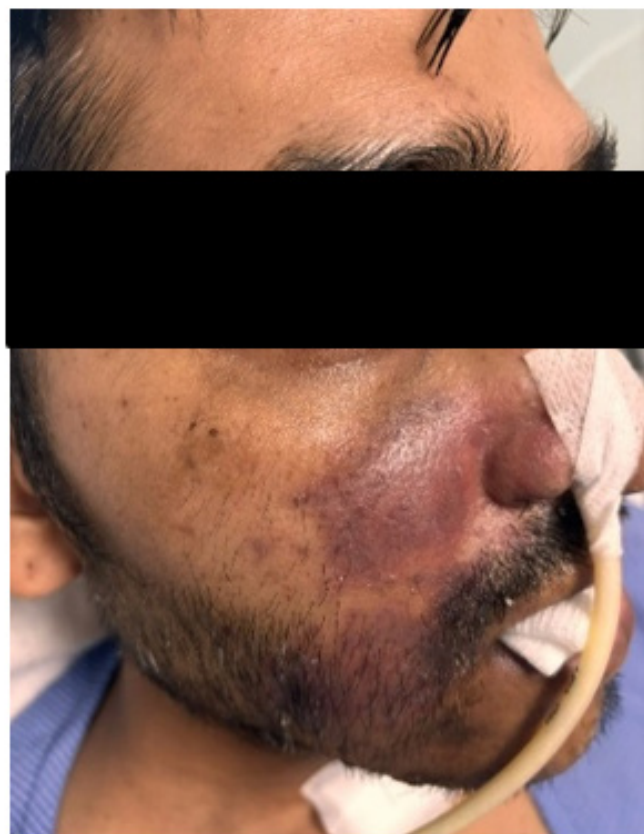

Figure 1: Non-pruritic erythematous maculopapular rash on the right cheek and perioral region noted during polymyxin B therapy. The rash was limited to the facial region and gradually resolved after discontinuation of the drug.

mediated through histamine release, melanocyte activation, and non-IgE-mediated inflammatory pathways (Kura and Sonawane, 2023; Mattos *et al.*, 2017; Zheng *et al.*, 2018). Similar pigmentary changes in Indian patients have also been described in earlier reports (Lahiry *et al.*, 2017; Kura and Sonawane, 2023).

The pathophysiology of these concurrent reactions can be explained by the dual toxicodynamic actions of polymyxin B on cutaneous and vascular tissues. The facial eruption likely represents a non-IgE-mediated inflammatory response driven by mast-cell histamine release and secondary cytokine activation, particularly interleukin-6 and downstream MAPK/PKA signaling, which cause dermal vasodilation and keratinocyte irritation (see Figure 2). Several reports have demonstrated melanocyte stimulation and histologic evidence of inflammatory pigmentation with polymyxin B therapy (Mattos *et al.*, 2017; Zheng *et al.*, 2018).

In parallel, the superficial thrombophlebitis observed at the infusion site can be attributed to endothelial irritation caused by the cationic, amphipathic structure and acidic pH of polymyxin B. These physicochemical properties disrupt endothelial membranes, activate platelets and local coagulation pathways, and promote localized vascular inflammation. Peripheral infusion amplifies this risk due to the smaller vessel caliber and reduced hemodilution compared with central venous access. Even with slow infusion rates and site rotation, repeated peripheral exposure can precipitate venous inflammation and thrombosis (Urbanetto *et al.*, 2016; Vardakas and Falagas, 2017).

The absence of deep-vein involvement in our patient further supports a localized vascular mechanism rather than a systemic thrombotic event. Although no biopsy was performed, clinical reasoning, temporal association, and causality assessment strongly suggest polymyxin B as the offending agent. In routine

Table 1: Summary of Polymyxin B-Induced Dual Adverse Reactions.

Adverse Reaction	Onset (Day)	Clinical Features	Investigations	Causality*	Outcome
Facial rash	Day 4 (after 7 th dose)	Non-pruritic maculopapular rash over cheeks and perioral area; no fever or eosinophilia	Dermatology review (no biopsy)	Probable	Resolved after drug discontinuation and antihistamine
Superficial thrombophlebitis	Day 4 (same day)	Pain, swelling, and induration at previous IV site	Doppler: thrombosis of cephalic, basilic, and median cubital veins; deep venous flow preserved	Probable	Improved with anticoagulation, local care, and central line placement

Causality assessed using Naranjo Adverse Drug Reaction Probability Scale (score 7) and World Health Organization - Uppsala Monitoring Centre system (both "Probable").

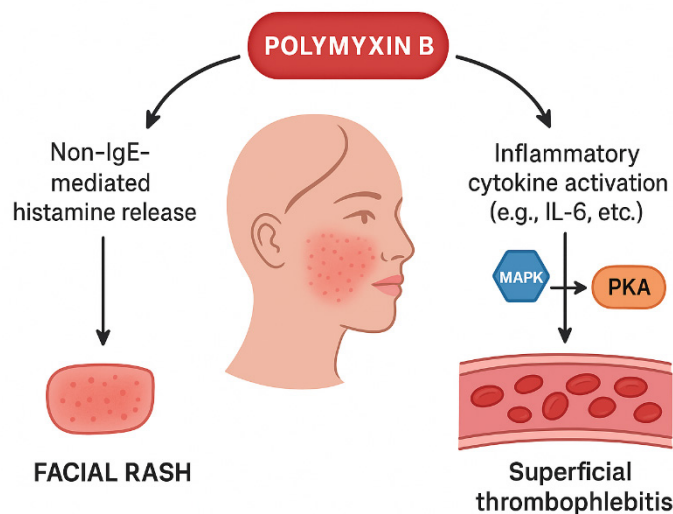


Figure 2: Proposed mechanism of polymyxin B-induced dual adverse reactions. Polymyxin B may trigger non-IgE-mediated histamine release, leading to a facial maculopapular rash, and simultaneously activate pro-inflammatory cytokines (e.g., IL-6) with downstream MAPK and PKA pathway involvement, resulting in endothelial injury and superficial thrombophlebitis.

clinical practice, dermatologists often omit biopsy when the reaction is mild, reversible, and temporally linked to a specific drug exposure.

Internationally, similar adverse events have been sporadically reported, although documentation remains limited. Reports from China have described rare cases of polymyxin B-induced skin hyperpigmentation (Zheng *et al.*, 2018), while infusion-site inflammation and phlebitis related to peripheral intravenous catheter use have been noted in critical-care settings (Urbanetto *et al.*, 2016). However, very few publications describe the simultaneous occurrence of cutaneous and vascular reactions, and none have specifically reported this presentation in head-and-neck cancer patients.

This dual presentation, corroborated by Doppler imaging and temporal correlation with polymyxin B therapy, adds to the growing recognition of underreported cutaneous-vascular adverse effects. These findings underscore the importance of pharmacovigilance and emphasize the need to avoid peripheral administration whenever feasible. Central venous access should be prioritized for anticipated prolonged therapy, and early dermatologic and vascular evaluation is essential to detect and manage such complications.

CONCLUSION

This case describes a rare dual adverse reaction to polymyxin B, with both a facial rash and superficial thrombophlebitis occurring simultaneously. Prompt discontinuation and supportive care led to full recovery. Early recognition, central venous access for prolonged therapy, and vigilant pharmacovigilance reporting are essential to prevent such complications and improve patient safety.

ACKNOWLEDGEMENT

The authors express gratitude to the Ruby Hall Clinic, Pune, India, for permitting the reporting of this case and for their clinical support during patient management.

ABBREVIATIONS

ADR: Adverse Drug Reaction; **ICU:** Intensive Care Unit; **IJV:** Internal Jugular Vein; **IV:** Intravenous; **MAPK:** Mitogen-Activated Protein Kinase; **MDR:** Multidrug-Resistant; **MIC:** Minimum Inhibitory Concentration; **PBA:** Polymyxin B Base Activity; **PK/PD:** Pharmacokinetics/Pharmacodynamics; **WHO-UMC:** World Health Organization-Uppsala Monitoring Centre.

CONFLICT OF INTEREST

The authors declare that there is no conflict of interest.

ETHICAL STATEMENT

Informed consent was obtained from the patient for publication of this case report and any accompanying images.

REFERENCES

- Kura, M. M., & Sonawane, P. D. (2023). Polymyxin B-induced skin and nail hyperpigmentation in an adult. *Pigment International*, 10(3), 183–185. https://doi.org/10.4103/pigmentinternational.pigmentinternational_82_21
- Lahiry, S., Choudhury, S., Mukherjee, A., Bhunya, P. K., & Bala, M. (2017). Polymyxin B-induced diffuse cutaneous hyperpigmentation. *Journal of Clinical and Diagnostic Research*, 11(2), FD01–FD02. <https://doi.org/10.7860/JCDR/2017/24278.9213>
- Mattos, K. P. H., Cintra, M. L., Gouvêa, I. R., Ferreira, L. Á., Velho, P. E. N. F., & Moriel, P. (2017). Skin hyperpigmentation following intravenous polymyxin B treatment associated with melanocyte activation and inflammatory process. *Journal of Clinical Pharmacy and Therapeutics*, 42(5), 573–578. <https://doi.org/10.1111/jcpt.12543>
- Tsuji, B. T., Pogue, J. M., Zavascki, A. P., Paul, M., Daikos, G. L., Forrest, A., Giacobbe, D. R., Viscoli, C., Giamarellou, H., Karaïskos, I., Kaye, D., Mouton, J. W., Tam, V. H., Thamlikitkul, V., Wunderink, R. G., Li, J., Nation, R. L., & Kaye, K. S. (2019). International consensus guidelines for the optimal use of the polymyxins: Endorsed by the American College of Clinical Pharmacy (ACCP), European Society of Clinical Microbiology and Infectious Diseases (ESCMID), Infectious Diseases Society of America (IDSA), International Society for Anti-infective Pharmacology (ISAP), Society of Critical Care Medicine (SCCM), and Society of Infectious Diseases Pharmacists (SIDP). *Pharmacotherapy*, 39(1), 10–39. <https://doi.org/10.1002/phar.2209>
- Urbanetto, J., Peixoto, C. G., & May, T. A. (2016). Incidence of phlebitis associated with the use of peripheral IV catheter and following catheter removal. *Revista Latino-Americana de Enfermagem*, 24, Article e2746. <https://doi.org/10.1590/1518-8345.0604.2746>
- Vardakas, K. Z., & Falagas, M. E. (2017). Colistin versus polymyxin B for the treatment of patients with multidrug-resistant Gram-negative infections: A systematic review and meta-analysis. *International Journal of Antimicrobial Agents*, 49(2), 233–238. <https://doi.org/10.1016/j.ijantimicag.2016.07.023>
- Zheng, G., Cao, L., Che, Z., Mao, E., Chen, E., & He, J. (2018). Polymyxin B-induced skin hyperpigmentation: A rare case report and literature review. *BMC Pharmacology and Toxicology*, 19(1), Article 41. <https://doi.org/10.1186/s40360-018-0226-1>

Cite this article: Dawaiwala I, Bhagat S, Zirpe K, Shah A, Deshmukh A, Muglikar P. Polymyxin B Induced Facial Rash and Superficial Thrombophlebitis: A Dual Adverse Drug Reaction. *Indian J Pharmacy Practice*. 2026;19(3):416-9.